

# THREE-DIMENSIONAL ANALYSIS ON DERMOSCOPIC IMAGES WITH RSA ENCRYPTED DIAGNOSIS

Divya Jayanadhan Nair<sup>1</sup>, Vishnu Prabha N Kaimal<sup>2</sup>

<sup>1</sup>M-Tech student, Applied Electronics and Communication Engineering, NCERC, Kerala, India

<sup>2</sup>Assistant professor, Dept of Electronics and Communication Engineering, NCERC, Kerala, India

\*\*\*

**Abstract** - There are many skin diseases in the present world. This leads to the death of a number of human beings. The main objective of the proposed work is to detect the early stages of melanoma. This proposed system introduces a noninvasive computerized dermoscopy system with RSA encryption. This method mainly concentrates in the detection of skin cancer depth and the result of analysis is secured by RSA encryption method. The skin lesion images of the patient which is in the 2D form are converted into 3D image after the depth estimation. Thus, the 3D skin lesion image is obtained by the depth analysis of the images. A 3D skin lesion reconstruction technique using the estimated depth obtained from regular dermoscopic images is presented. On basis of the 3D reconstruction, depth and 3D shape features are extracted. In addition to 3D designed to diagnose basal cell carcinoma, blue nevus, dermatofibroma, haemangioma, seborrheic keratosis and normal mole lesions. For experimental evaluations ISIC 2016: Melanoma Project datasets is considered which is freely available on net. Significant performance improvement is reported post inclusion of estimated depth and 3D features. RSA encryption will be applied on the result generated after the diagnosis.

**Key Words:** 3D skin lesion, melanoma, blue nevus, dermatofibroma, haemangioma, seborrheic keratosis, ISIC dataset, RSA encryption.

## 1. INTRODUCTION

As there are the increasing skin diseases in the world, the world health organization declares that skin cancer is the increasing disease [1]. Thus, there are various types of skin cancer can be classified as melanoma and the non-melanoma category [2]. The diagnosis of the skin disease can be done at the early stages. The death rate due to the skin cancer in the united states alone will be 75%. The person who are having the melanoma skin cancer will die more than the person having non-melanoma skin cancer [3][4]. There is an annual increase in the death rate per year is 2.6%. Thus, the early detection of skin cancer melanoma is achieved. The five year survival rate of 95% is reported. The survival rate of skin cancer is 13% [5]. Thus, the early detection of skin cancer is the important factor. The proposed method consists of dermoscopy technique

which consists of non-invasive technique. Dermoscopy is the technique which is performed as applying the gel liquid in the lesion region. This method is known as stereomicroscope or dermatoscope which is used to magnifying the images. They are characterized by the skin color, structure and the pattern data of the skin region. The data which is gathered cannot be visible with the human eye. Thus, the skin lesions are identified with the above data and diagnosis them [7]. Many dermatologists use many algorithm such as ABCD (Asymmetry, Border, Color and Diameter) [8], ABCDE (Asymmetry, Border, Color, Diameter and Evolution) [9]

Menzies method [10] and the seven-point checklist [11]. These methods are undergone by the diagnosis of skin cancer. By these method, detection of skin cancer is about 5-30% easy and accurate. This will be easy for the practice of dermatologists. These cannot be carried out using naked eye [12].

## 2. LITERATURE SURVEY

A Multi Parameter Extraction and Classification System (MPECS) is proposed to distinguish early melanoma [12]. A six stage approach is [11] adopted to remove the colour, texture and shape highlights. Grouping of three skin injury types, to be specific "Progressed Melanoma", "Non-Melanoma", "Early Melanoma" is accomplished and not clarified about the precise profundity of the tumor into favorable or harmful sorts. The utilization of traditional clinical calculations, for example, ABCD (Asymmetry, Border, Color and Diameter) [8], ABCDE (Asymmetry, Border, Color, Diameter and Evolution) [9], Menzies strategy [10] and the seven-point agenda [11] is received by for the analysis of melanoma skin sores.

## 3. METHODOLOGY

The image processing techniques consists of following steps.

### 3.1 IMAGE ACQUISITION

Image acquisition is getting the input image through various sources such as camera or through x-ray, MRI scanning, CT scan and microscopic analysis. Thus, the image acquisition can be done in various input format such as jpeg, jpg, bmp and png format.

### 3.2 PRE-PROCESSING

Pre-processing stages consist of various methods and various steps included in image processing techniques. They include

### 3.3 GRAY-SCALE CONVERSION

Preprocessing stage consists of color conversion and filtering process. The input retinal images can be in the form of RGB images. These RGB images are converted into gray scale images. RGB images are converted into gray scale images due to the elimination of hue and saturation of the input images.

### 3.4 FILTERING

Filtering process is done to eliminate the noise within the image. The filter which is used in the proposed work is the median filter. Median filter is used to eliminate the noise within the retinal images and also used to smoothen the retinal images. By eliminating the salt and pepper noise, the skin lesion images can be smoothen.

### 3.5 SEGMENTATION

Segmentation process is carried out to separate the lesion region from the other regions of the skin. The segmented part undergoes the various classification procedures to find the early stages of skin lesions.

### 3.6 CLASSIFICATION

The classification process can be undergoes for the early stage detection of skin lesions in the human. There are various stages of classifiers which is namely SVM(support Vector Machine), Multi class SVM and ANN (Artificial Neural Networks). They are used to analysis the various stages of skin cancer in the diseased persons.

## 4. PROPOSED SYSTEM

The Block diagram of the proposed work can be shown in the figure 4.1

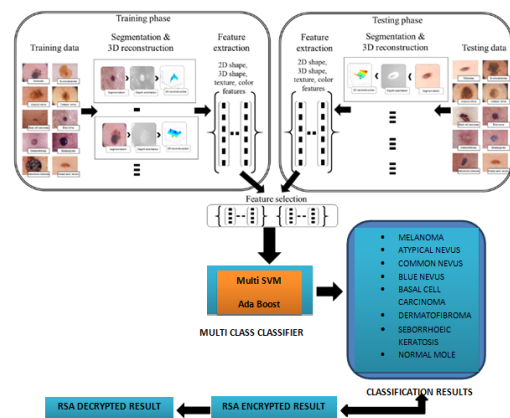


Figure 4.1 Block diagram of the proposed work.

### 4.1 IMAGE ACQUISITION

The input 3 dimensional images are acquired from the clinical database. They have the collection of various skin lesions patient images. More than n number of patient's stages can be analyzed using image processing technique. The image acquisition stage is followed by the pre-processing stage.

### 4.2 PRE-PROCESSING

This stage consists of various steps such as gray-scale image, filtering process. Thus, the output of these stages are shown in the figure 4.2




Figure 4.2 Graphical user interface short screen.

### 4.3 SEGMENTATION

Pre-processing stages is followed by the segmentation process. The segmentation process is carried out using adaptive snake model algorithm .This algorithm is carried out to separate the minor regions of the skin lesions .The final stages of segmentation in shown in the figure 4.3

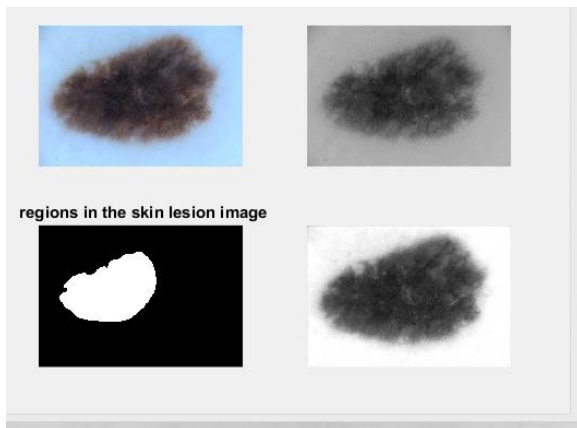


Figure 4.3 Segmentation

Mapping is done to segment the lesion region and to find the feature extracted from the segmented region. Thus, the intermediate result is shown in the figure 4.4

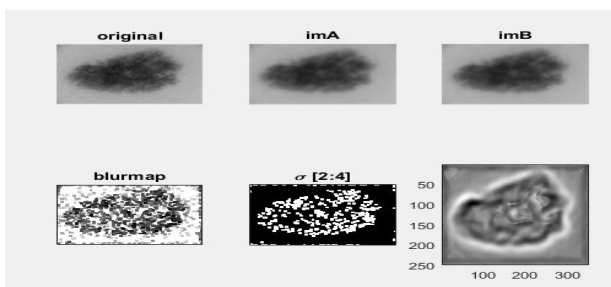


Figure 4.4 Intermediate result of Feature extraction

#### 4.4 FEATURE EXTRACTION

Feature extraction is considered as the important step, it helps in the classification process. In this paper 3D reconstruction of image is done from the 2D dermoscopic image by estimating the depth. On the basis of 3D reconstruction, 3D shape feature, 2D shape feature, color and texture are extracted, in figure 4.6 final 3D reconstruction of image is shown from 2D dermoscopic image.

#### 4.5 CLASSIFICATION

Final step is the classification process, the accuracy of classification mainly depends on how accurately segmentation and feature extraction is done the classification process is carried out using Two classifiers used here Ada boost and multi SVM to compare the performance of classifier. This will identify the type of skin lesions.

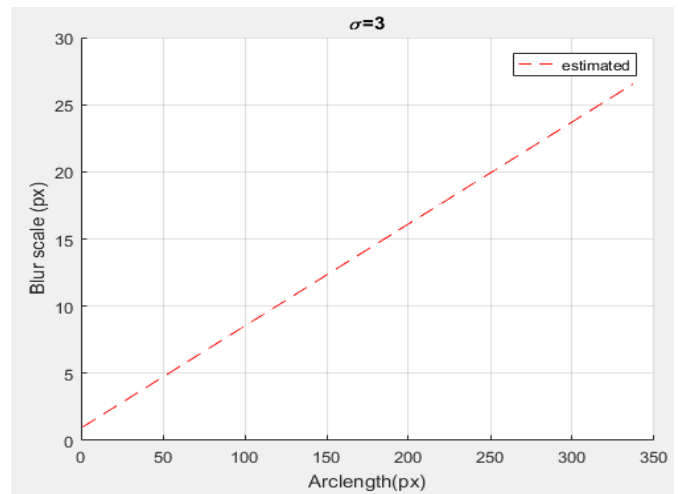


Figure 4.5 Blur scale graph representation

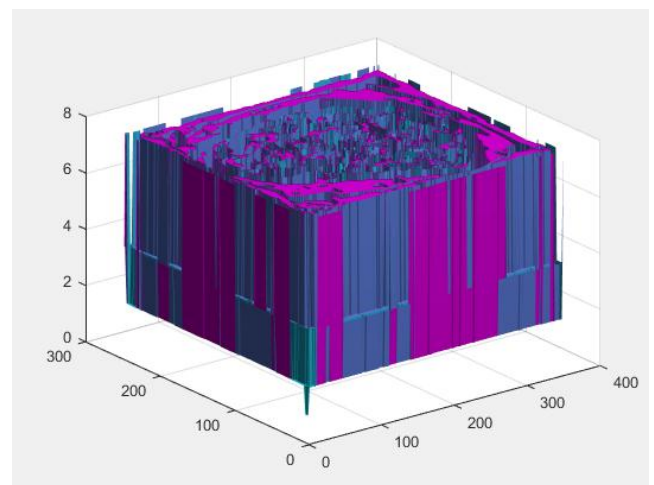


Figure 4.6 Final 3D reconstruction of image from 2D dermoscopy image.

Two classifiers used here Ada boost and multi SVM to compare the performance of classifier.

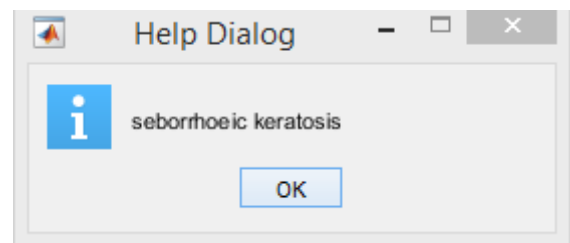


Figure 4.7 Final classification

#### 4.5 PERFORMANCE METRICS

Thus, the accuracy and the encryption and decryption process is carried out as shown in the figure 4.8 and in figure 4.9 performance graph of two classifiers is shown.

accuracy  
98.6949

Figure 4.8 Accuracy.

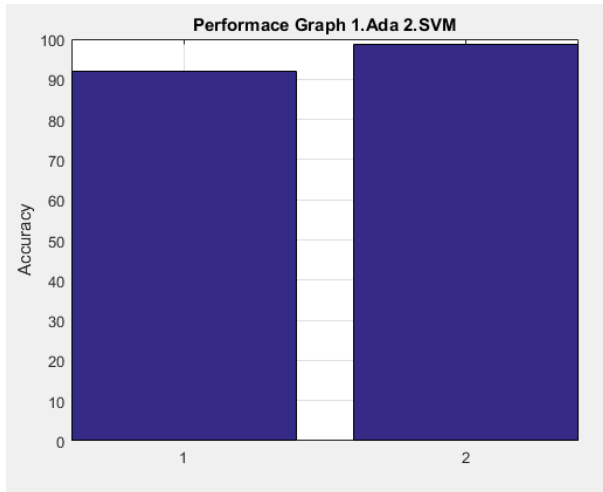


Figure 4.9 short screen of performance graph.

From the performance graph of two classifiers ada boost and Multi-Svm, it is clear that the accuracy rate Multi Svm is more (98.69%) than the Ado boost classifier (92%). Final result is encrypted for security purpose, RSA algorithm is used, and 32 bit key is used here.

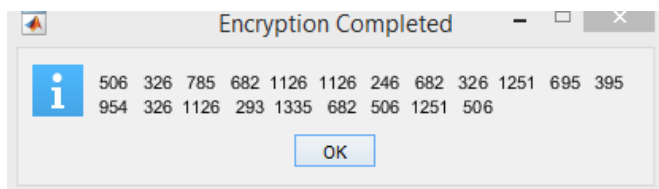


Figure 4.10 Encrypted data.

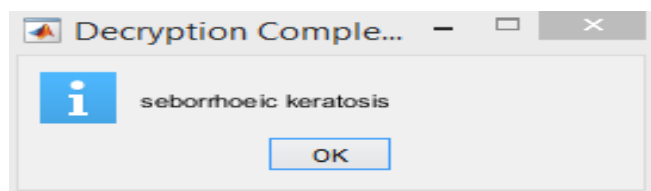


Figure 4.11 Decrypted data.

## 5. CONCLUSION

Thus, by the proposed method there is a reduction in the time consumption. It will be useful for the practice of the dermatologist. IN future, classification process may change with better algorithm which would analysis more number of diseases.

## REFERENCES

- [1]WHO inter sun (2015) <http://www.who.int/uv/faq/skincancer/en/index1.html> (accessed 21 July 2015.).
- [2] L. Baldwin and J. Dunn, "Global Controversies and Advances in Skin Cancer," Asian Pacific Journal of Cancer Prevention, vol. 14, no. 4, pp. 2155-2157, 2013.
- [3] American Cancer Society, Cancer Facts & Figures 2015: American Cancer Society 2015
- [4] N. Howlader, A. Noone, M. Krapcho, J. Garshell, N. Neyman, S. Altekruse, C. Kosary, M. Yu, J. Ruhl, Z. Tatalovich, H. Cho, A. Mariotto, D. Lewis, H. Chen, E. Feuer, and K. Cronin. (2012, Apr.). "SEER cancer statistics review, 1975-2010," National Cancer Institute, Bethesda, MD, USA
- [5] U.S. Emerging Melanoma Therapeutics Market, a090-52, Tech. Rep., 2001
- [6] H. Pehamberger, A. Steiner, and K. Wolff, "In vivo epiluminescence microscopy of pigmented skin lesions—I: Pattern analysis of pigmented skin lesions," J. Amer. Acad. Dermatol., vol. 17, pp. 571–583, 1987.
- [7] J. Mayer, "Systematic review of the diagnostic accuracy of dermatoscopy in detecting malignant melanoma," Med. J. Aust., vol. 167, no. 4, pp. 206–210, Aug. 1997.
- [8] W. Stolz, A. Riemann, and A. Cagnetta, "ABCD rule of dermatoscopy: A new practical method for early recognition of malignant melanoma," Eur. J. Dermatol., vol. 4, pp. 521–527, 1994.
- [9] A. Blum, G. Rassner, and C. Garbe, "Modified abc-point list of dermoscopy: A simplified and highly accurate dermoscopic algorithm for the diagnosis of cutaneous melanocytic lesions," J. Am Acad. Dermatol., vol. 48, no. 5, pp. 672–678, May 2003.
- [10] S. Menzies, C. Ingvar, K. Crotty, and W. McCarthy, "Frequency and morphologic characteristics of invasive melanomas lacking specific surface microscopic features," Arch. Dermatol., vol. 132, no. 10, pp. 1178–1182, Oct. 1996.
- [11] G. Argenziano, G. Fabbrocini, P. Carli, V. De Giorgi, E. Sammarco, and M. Delfino, "Epiluminescence microscopy for the diagnosis of doubtful melanocytic skin lesion.